Healthy Thoracic Spine Function for Healthy Shoulders

Introduction

In this article we will specifically look at:

- How the thoracic spine's function will influence injury risk to the shoulder.
- What good thoracic spine function actually is.
- How to improve thoracic spine function.

Thoracic spine and the glenohumeral joint

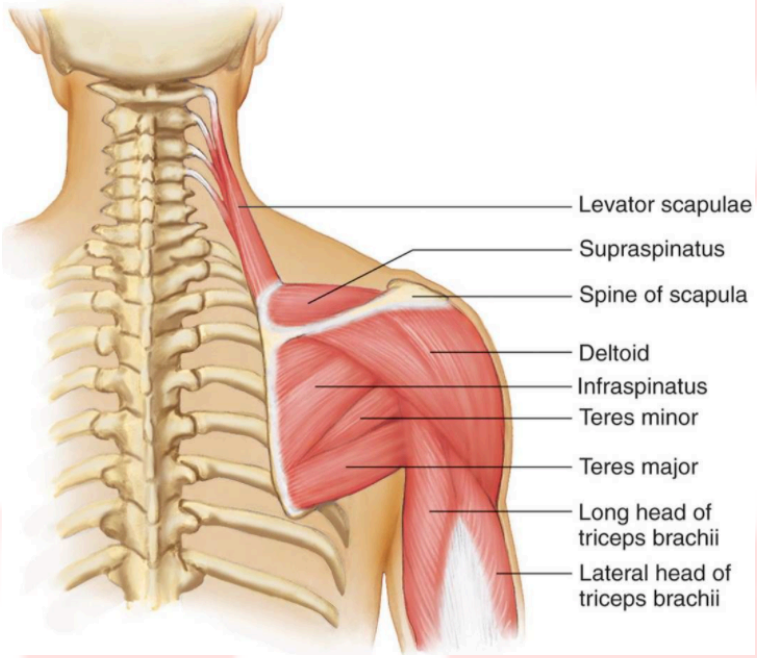

Thoracic spine function is vital in preserving health to the glenohumeral joint, reducing the risk for shoulder joint injuries. This is largely due to its' relationship with the scapula.

The scapula is integral to the stability of the glenohumeral joint as it provides the insertion point for the rotator cuff muscles amongst others that stabilise the joint (see diagram). Many of the muscles that attach to the scapula originate on the ribs, therefore it is the orientation of the ribs that either promote or inhibit good scapula alignment. Optimal alignment of the thoracic spine (and thus scapula) will allow the key stabilising muscles of the shoulder to produce higher force, thus protecting the shoulder complex.

Mechanisms for injury

For good function, the shoulder complex should be capable of 180 degrees of shoulder flexion. The glenohumeral joint is responsible for around 120 degrees of this, with the remaining 60 degrees being supplied by the scapulothoracic joint (acromioclavicular and sternoclavicular joint movements combined).

The thoracic spine should also be capable of around 10-11 degrees of extension from 'neutral'. This extension should form part of any healthy, overhead lifting mechanics. The inability to achieve either full shoulder flexion or thoracic extension, will inevitably cause neighbouring joints and tissues to compensate in order to reach the desired final overhead lifting position.

Additionally, when extended, the thoracic spine is capable of more rotation than when flexed due to the tension created by the ligamentous structures. This is especially important when reaching overhead and behind.

Typical injuries

Impingement

Poor thoracic spine alignment will cause abnormal kinematics at the glenohumeral joint. When this is the case, repetitive motions and altered mechanics may result in pathophysiological changes within the rotator cuff tendons, labrum, subacromial bursa and long head of the biceps brachii. These changes can lead to impingement syndrome.

Abnormal scapular kinematics during shoulder elevation tasks have also been linked to glenohumeral joint pathologies related to impingement.

Rotator cuff tears

Over-reaching against a joints' given range of motion can lead to tears in the relatively weaker stabilising rotator cuff muscles.

Assessing thoracic motion

The following screening methods can be used to assess thoracic function. Please note, the screening tests should be done un-resisted and resisted to see changes in kinematics.

Thoracic extension – Bilateral shoulder flexion test protocol:

1. The athlete should stand with their feet apart with the arms in the resting position by their side.
2. The athlete raises both arms, keeping the elbows extended and the palms of the hands facing the midline.
3. Angle change measurements from T1/T2 and T12/L1 vertebra can be made via inclinometers (available as an app on smart phones).

TRAINERMAKER





Thoracic extension – Occiput to wall test protocol:

This is a practical test that does not require specialised equipment.

1. The athlete leans back against a wall, knees slightly flexed and feet one foot-length away from the wall.
2. With the sacrum and upper back in contact with the wall, the athlete posteriorly tilts the pelvis flattening the lumbar spin.
3. From this position the athlete attempts to make contact between the wall and their occiput, while maintaining a neutral head position. This aught to be possible with adequate thoracic extension.

TRAINERMAKER

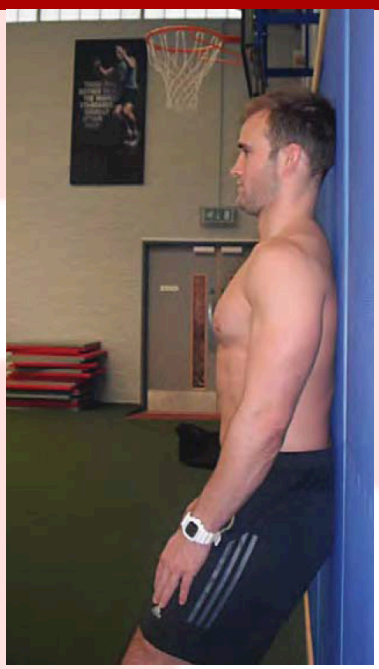

Thoracic rotation – Standing rotational reach test protocol:

This test can show a athlete's total body rotational capacity. Upper body as well as lower body rotational capacity can be assessed and compromise strategies noted

1. The athlete should stand with feet hip width apart.
2. With one hand by the side and the other reaching across the body, the athleter should rotate around as far as possible as if trying to look behind them
3. The athlete should be able to rotate their pelvis 45 degrees from neutral in the transverse plane. The shoulders should show a further rotation of 45 degrees beyond the hips either ipsilateral or contralateral.

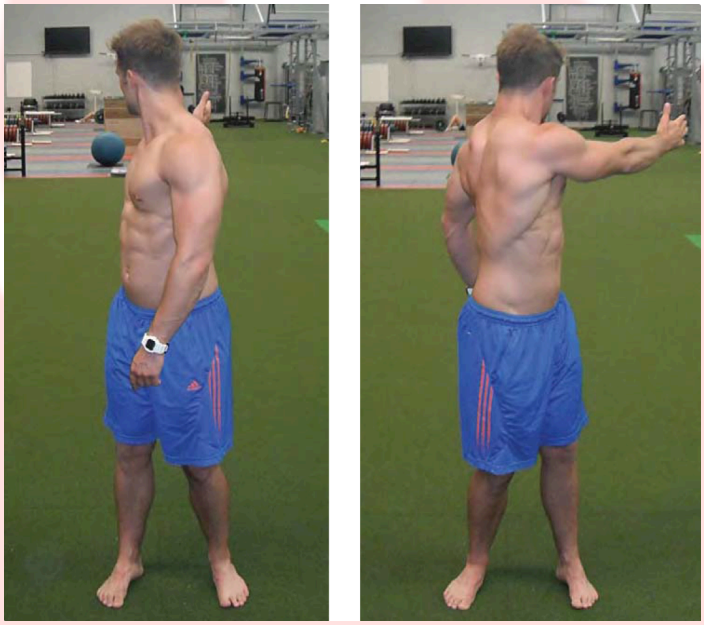

Thoracic rotation – Seated rotation test

The seated thoracic rotation test takes out contributions from the lower limbs.

1. athlete to sit on a chair with hips and knees flexed to 90 degrees.
2. A small ball can be placed between the knees to pevent any movement at the pelvis.
3. A bar is held in front of the body.
4. The athlete should rotate to either side as far as possible.
5. A goniometer can be used to assess rotation. It should be placed at T1/T2 and oriented parallel to the floor. The moving arm should be aligned with the scapula. Again, 45 degrees is optimal rotation.





Examples of thoracic rotation mobilisations